

A CLINICAL ANALYSIS OF PATIENTS WITH WRIST DROP DUE TO RADIAL TUNNEL SYNDROME

Vaner Köksal *, Kenan Kıbıcı, Serkan Kırbaş

*Recep Tayip Erdoğan University, Medical School, Department of Neurosurgery, Rize, Turkey
Kemerburgaz University, Medical School, Department of Neurosurgery, İstanbul, Turkey
Recep Tayip Erdoğan University, Medical School, Department of Neurology, Rize, Turkey

Abstract

Objective

The wrist drop caused by damage to radial nerve is a very rare condition. The aim of the current study is to present our diagnostic and treatment criteria in radial tunnel syndrome.

Methods

We performed a retrospective study on 16 patients. Between January 2006 and June 2014, the clinical assessment of consecutive operated patients with radial tunnel syndrome in Rize Education and Research Hospital and Kasımpaşa Military Hospital were analysed. The diagnosis and severity of syndrome was based on electrodiagnostic study after 2 weeks that revealed delayed nerve conduction velocity in all patients.

Results

Patients with radial tunnel syndrome were 12 men and 4 women; median age, 28 years; range, 8–37 years. The right arm was affected in 8 patients and the left arm in 8 patients. 10 patients were treated with surgery and 6 patients were treated without surgery (conservative). Despite 3-week-conservative treatment, surgical decompression was performed in the patients unresolved clinic symptoms.

Conclusion

Rapid clinical improvement was occurred in the patients with surgical decompression. The radial nerve entrapment was always in the dominant arm. The outcome was better in patients with surgery compared with patients with conservative treatment.

Keywords:

Hand drop, Supinator tunnel syndrome, Radial nerve, Entrapment, wrist drop.

Introduction

The wrist drop is caused by entrapment of the radial nerve. And it is called the radial tunnel syndrome (RTS). RTS is usually a painful syndrome in the proximal forearm. And, caused by compression of the posterior interosseous nerve (PIN) at the proximal forearm (1-3). It is usually occur to nerve compression while crossing beneath the supinator muscle (4,5). This syndrome was also called the posterior interosseous nerve paralysis (PI), supinator tunnel syndrome, traumatic progressive paralysis of the deep branch of the radial nerve, “Saturday night syndrome”, or even “Frohse’s syndrome” since it demonstrates an acute development (6). The typical “wrist drop” appears in the presence of a strong and long lasting compression due to the dysfunction of the extensor muscles on wrist. The most common causes of radial neuropathy are direct trauma to the nerve or prolonged pressure on the nerve from compression, swelling, or injury of nearby structures. Other reasons, fibrous bands located above the radial head; recurrent radial vessels jumping over the nerve in the area most proximal to the lateral epicondyle, which increase blood flow to the extensor, supinator and brachialis muscles during exercise, compressing the PIN (3). Also, the radial nerve is frequently injured during a fracture of the distal 1/3 of the humerus (just above the elbow in the upper arm) or upper forearm (proximal radius just below the elbow) (7). Symptoms are aggravated by simple movements of the forearm and wrist.

RTS is a quite rarely seen pathology and so the definitive incidence is not clear. The annual incidence rate of the PIN compression is estimated 0.03% while the rate for superficial radial nerve compression is 0.003%. In comparison, the most common neuropathy, carpal tunnel syndrome, has an annual incidence between 0.1% and 0.35% in the general population (8,9). In this paper, our diagnostic and surgical treatment criteria in patients with wrist drop were analysed. We investigated the optimal timing for surgical decompression.

Materials and methods

From January 2006 to June 2014, a retrospective study was performed on 16 patients diagnosed with radial nerve entrapment in neurophysiologic analyses among patients who had experienced wrist drop in the Department of Neurosurgery in Kasımpaşa Military Hospital and Rize research and education hospital. Electrophysiologic evaluation was performed after 2 weeks that revealed delayed nerve conduction velocity in all patients. 10 patients were treated with decompressive surgery consist of supinator muscle myotomy. Findings on EMG were considered positive for radial tunnel syndrome when the motor conduction velocity (MCV) across the forearm is less than 50 m/sec. MCV is 45 – 50 m/s and sensory distal latency is 3.5 – 4 ms which cases were considered mild (10). 6 patients were treated without surgery.

First, In all patients, the wrist was rested at least 3 weeks and with clinical follow-up. At the end of week 3, patients who did not show any clinical improvement were performed myotomy under regional intravenous anesthesia (RIVA). Patients' demographic data and information on individual clinical features such as motor and sensory presentations, related postures, individual neural compression times, and clinical improvement were retrieved from medical records. Radiological viewing for individual with MRI scan was obtained After clinical examination (figure 1a). Anti-inflammatory treatment and physical treatment was started. Electrophysiological tests were performed on all patients at the end of 2 weeks period and radial nerve entrapment underneath the supinator muscle was detected. If conservative treatment fails to improve patients symptoms then surgical treatment is indicated. All patients were followed between 3 months -2 years after the development of wrist drop. Surgical and conservative outcomes were evaluated using the criteria of Ritts et al (11). (Good = minimal or no discomfort, Fair = subjective and objective improvement, but with moderate pain limiting capacity to use involved extremity, Poor = moderate to severe discomfort after the operation.) Clinical results of the patients showed on table 1. All 16 patients had received conservative treatment, including splinting, antiinflammatory medication, or physical therapy, but failed to obtain adequate relief in 10 patients. Similarly, the same splint application was initiated in the other patients without surgical treatment who were started with active exercises during the acute stage and demonstrated clinical improvement. A special flexor splint was fixed at the hand wrist to increase the strength and facilitate the activities of extensor muscles (figure1d).

Anatomy of the radial nerve

Radial nerve is divided into two terminal branches at the proximal forearm over the annular ligament. The superficial branch is the sensorial branch (2). The deep branch of the radial nerve passing beneath the supinator muscle is called the posterior interosseous (PI) nerve that motor branch. The deep branch pierces the supinator canal (or tunnel) where the extensor carpi radialis brevis (ECRB) muscle takes its origin (figure 1b). Tunnel approximately 1 cm long. Formed by the restriction of ECRB muscle is called the arcade of Frohse. The nerve enters the supinator muscle after passing under the arcade of Frohse (12). This tunnel is not an anatomically existing structure. Since the nerve passes beneath the muscle, a functional tunnel is described. Radial nerve may be exposed to a dynamic compression due to the activity in the supinator muscle owing to its anatomical state.

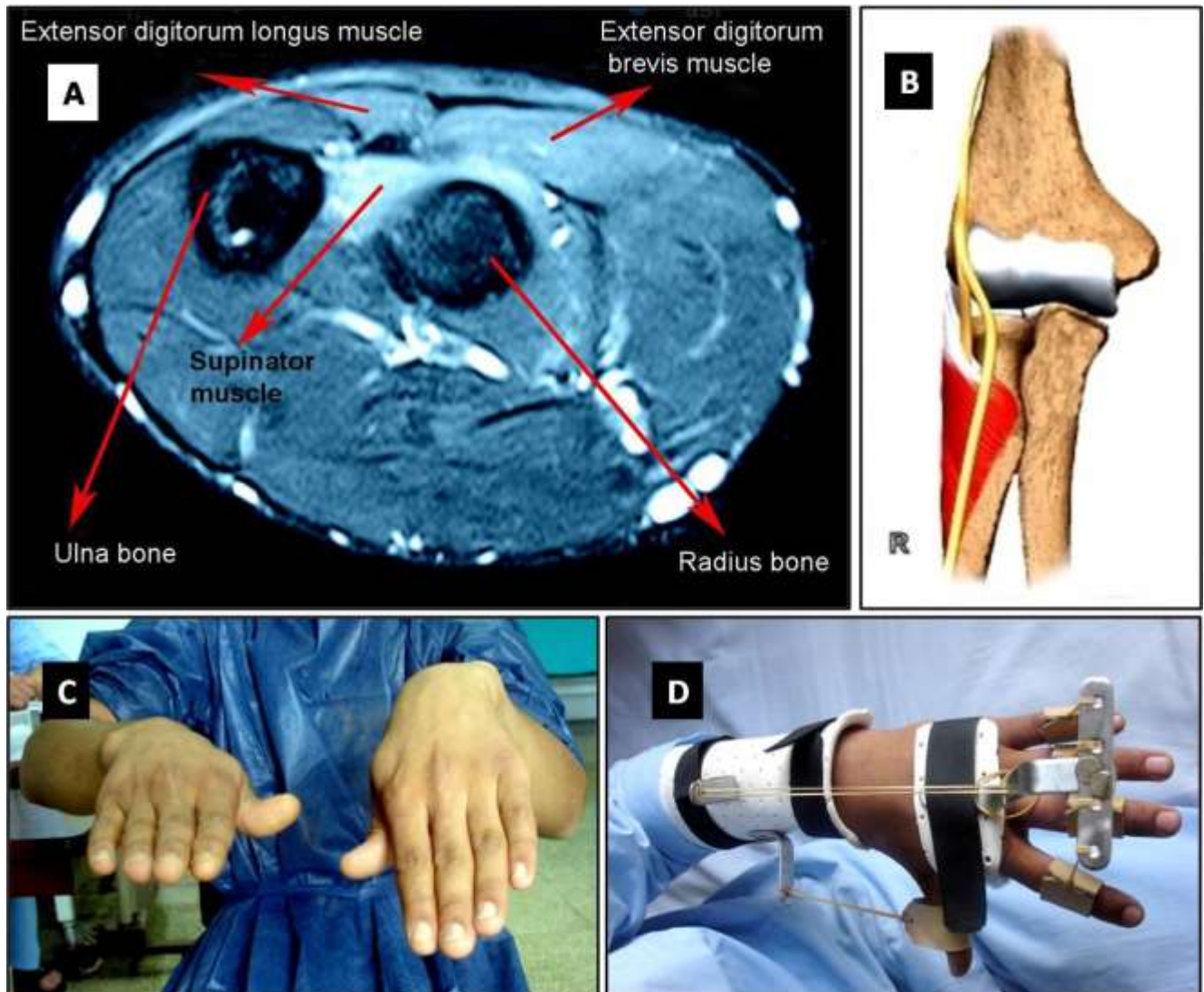


Figure 1: MRI image, course of the radial nerve and physical examination findings.

1a: Appearance of the axial cross-section of MR image passing through the distal of the elbow. Edema of the muscle to be followed.

1b: Anatomical course of the radial nerve at the level of the elbow

1c: Appearance of a patient with wrist drop.

1d: A special application of splint which causes extension at the wrist of the hand

Surgical method

The surgical intervention was applied over the supinator muscle, encasing the radial nerve motor branch (the deep branch) tightly. The patient was placed in a supine position on the operating table with left or right arm (figure 2) situated on his own body by positioning the elbow facing the surgeon and forearm back looking upward. This approach is the postero-lateral approach (3). Dissection was planned on the posterior surface of the forearm. A skin incision (Figure 2a) approximately 10 cm long was made at the left arm elbow level on the proximal of the line drawn starting from the top of the lateral epicondyle passing through the mid-point on the dorsal surface of the hand wrist just above the level of the left arm elbow on the dorsal surface of the hand towards the dorsal surface of the hand wrist.

Radial nerve at elbow level, in lateral epicondyle neighborhood or point of emergence of the radius and brachioradialis bone in the distal arm and was followed towards the distal and location of entrance beneath the supinator muscle is found, or in direct contradiction, after the decided skin incision is opened, PI nerve appearing beneath the supinator muscle at the distal arm is found and followed to the proximal backwards. The supinator muscle is entered through a dissection by extending outwards at the line of incision between the extensor digitorum communis muscle and the ECRB muscle in the forearm extensor compartment (Figure 2b). As soon as the supinator muscle is cut along the radial nerve or PI nerve trace it is decompressed (Figure 2c). Supinator muscle after the appearance of the skin incision is being monitored during surgery (Figure 2d). As a result, supinator muscle myotomy surgery was performed.

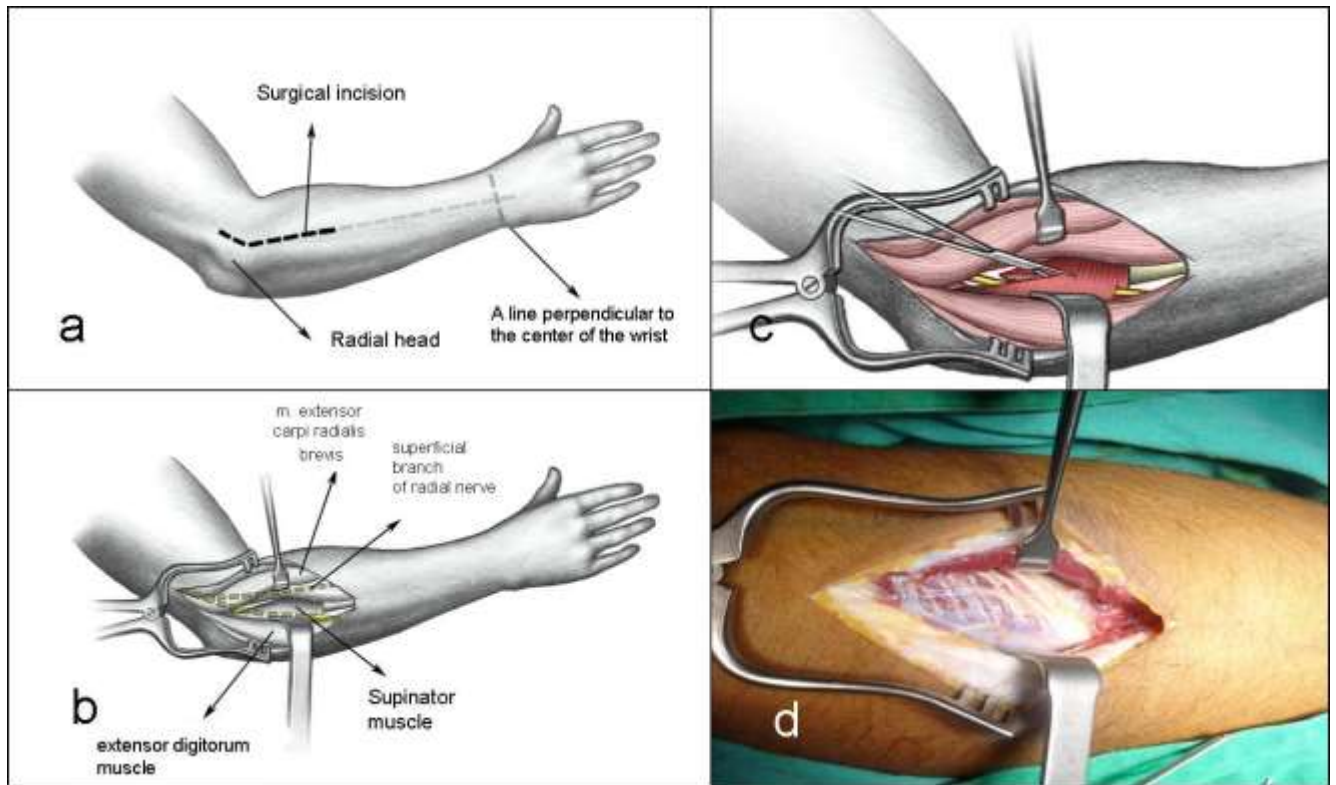


Figure 2: Description of the surgical plan with detailed illustrations.
2a: Incision plan and important anatomical points used for this plan.
2b,2d: Entry into the supinator muscle after the surgical incision.
2c: Perform of myotomy through the supinator muscle.

Results

Patients were 12 males and 4 females. The median age at diagnosis was 28 years (range, 8 – 44 years). The right arm was affected in 9 patients and the left arm in 6 patients. Surgery was performed on 10 patients. 6 patients were treated without surgery. The surgical results were rated as good (70%) by 7 patients, fair (20%) by two patients and poor (10%) by one patient. The clinical features of the patients with radial nerve entrapment are displayed on table 1 (Table 1). Improvements in strength through dorsal flexion (wrist extension) of the hand and wrist were observed during post-operative early period.

Table 1: The clinical summary of the patients.

Case No	Age	Gender	Site	Dominant arm	Etiology	Symptom duration (weeks)	Treatment method	Total clinical recovery time (weeks)	Prognosis
1	21	Male	Right	Right	Soldier	4	Conservative	8	Good
2	30	Female	Left	Left	Banker	4	Conservative	6	Good
3	21	Male	Right	Right	Soldier and fracture	Subacute	Conservative	9	Fair
4	8	Male	Left	Right	Fracture	Subacute	Conservative	6	Fair
5	34	Female	Left	Left	Housewife	3	Conservative	9	Good
6	21	Male	Left	Left	Fracture	Subacute	Conservative	8	Good
7	20	Male	Right	Right	Student	5	Surgery	4	Good
8	23	Male	Right	Right	Electrician	Acute	Surgery	12 — today	Poor - Bad
9	44	Female	Right	Right	Housewife	13	Surgery	10	Fair
10	27	Male	Left	Left	Banker	8	Surgery	5	Good
11	32	Male	Left	Left	Cook	7	Surgery	4	Good
12	21	Male	Right	Right	Soldier	14	Surgery	9	Fair
13	22	Male	Left	Left	Soldier	7	Surgery	4	Good
14	25	Male	Left	Left	Electrician	6	Surgery	5	Good
15	37	Female	Right	Right	Cook	6	Surgery	6	Good
16	28	Male	Right	Right	Mechanic	5	Surgery	5	Good

Development of wrist drop due to isolated radial tunnel syndrome was observed in the left hand of left-hand-dominant subjects, and in the right hand of right-hand-dominant patients. As well as wrist drop, complaints characterized by varying levels of lateral elbow pain were observed in the patients. Despite 3-week-conservative treatment, surgical decompression was performed in the patients unresolved clinic symptoms. Rapid clinical improvement was occurred in the patients after surgical decompression. The radial nerve entrapment was always in the dominant arm and the severity of entrapment increased with by repetitive pronation movement. Despite the surgery in one case, The patient was not recovery. All patients had received conservative treatment, including splinting, anti-inflammatory medication and physical therapy during 4 – 6 weeks. Electrophysiological evaluation of patients which operated for radial tunnel syndrome is shown in table 2 (table 2). A complete clinical improvement was observed between the second and sixth months in all subjects except one. Normal electrophysiological findings were obtained from the EMG examinations performed on the sixth month of follow-up.

Table 2: Pre and post-operative electrophysiological evaluation of patients with surgery.

Case No	Site R/S	SNAP(μ V/)		cMAP (m/V)		Sensorial conduction velocity.	
		preoperative	postoperative	preoperative	postoperative	Preoperative	postoperative
7	R	8	10	2	4	43	54
8	R	Non	Non	1	4	Non	25
9	R	Non	2	2	4	Non	40
10	L	5	8	4	6	40	48
11	L	3	10	4	8	41	56
12	R	5	8	3	6	43	54
13	L	6	9	1	3	42	52
14	L	4	10	2	5	44	55
15	R	5	9	2	4	39	50
16	R	7	11	3	5	42	58

(Non=No response, R=Right, L=Left.)

Normal the ranges of values of the radial nerve;

Normal radial sensory nerve action potential (SNAP) values include an amplitude of $\geq 10 \mu$ V, a peak distal latency of ≤ 2.8 ms, and a velocity of ≥ 50 m/s

Normal radial compound motor action potential (cMAP) values include an amplitude of ≥ 4 mV, a peak distal latency of ≤ 3.3 ms, and a velocity of ≥ 50 m/s (13).

Discussion

Compared with other entrapment neuropathies of the upper extremity, RTS is not widespread and still more controversial (5). Diagnosis is based on clinical suspicion. "In the morning, my hand does not get back up! I woke up with pain in my hand and I found this form what my wrist." This complaints are common for RTS. But it is difficult to decide for RTS. Pain in elbow and wrist drop were pathognomonic for RTS but not %100 sensitive. Additionally, the possibility of similar severe pain of elbow back in lateral epicondylitis and C6 cervical radiculopathy should not be forgotten. Other pathologies which may lead to wrist drop should be distinguished in the differential diagnosis. That's why, electrophysiological evaluation is important for the differential diagnosis. Electrophysiological tests were performed on all our patients at the end of 2 weeks. Patients with RTS should be treated conservatively before considering surgical intervention (1). This is a classic knowledge recognized for a long time. We decided that it was wrong. Because, ongoing wrist drop. Surgery was necessary, but when? Thus, We try to determine what the waiting time for surgery in RTS.

When all factors were combined, wrist drop clinic suddenly developed in the morning, as described in the patient's episode due to exposition to ischemia owing to long-term compression. A clinical manifestation similar to the literature emerged since humans sleep in a non-physiological position during nights (14). We believe that wrist drop clinic occurs easier in people who perform tasks or have related past episodes leading to tightening of the supinator tunnel. We have proved with our clinical experience. In patients undergoing conservative treatment, the type of injury is a "neuropraxia" that does not involve damage to the axon. Neuropraxia is classified as a transient conduction block of motor or sensory function without neuronal degeneration. Therefore, despite decreased motor function, patients with neuropraxia (13). This pathology is probably due to mechanical compression and edema developing as a result of over hardening of the supinator muscle like a tendon at the nerve entrance. Continuous pain and lack of strength in the hand and finger extensors of 11 violin players were proved to be due to intermittent functional impairment of the deep branch of the radial nerve (15). 2 of our cases in the same way suddenly appeared and they was recovered with conservative treatment.

There are contradictory ideas about the cause of RTS. But, Anatomical compression was ascertained to be the leading cause of the of the RTS as a result of the studies. RTS is caused by continuous or intermittent compression

of the PIN distal to the elbow (16). However, superficial fascia thickness within the capsule of the elbow, vascular structures, fibrosis, fibrous edge of the ECRB muscle and the supinator muscle itself were reported to contribute to the anatomic compression (8). We were found hypertrophic supinator muscle except case 7 and 10 in patients undergoing surgery. In all our cases without radial bone fractures were found to occur in the dominant arm of the radial nerve entrapment. With this feature, radial or supinatory tunnel syndrome was different from entrapment in the cubital tunnel tunnel (17). the RTS was comprised in dominant arm (extremity) such as carpal tunnel syndrome and peroneal nerve entrapment (18).

Some repetitive physical activities may cause stretching and compression in the supinator tunnel. It was reported that tunnel may tighten especially during repetitive pronation, forearm extension and simultaneous hand wrist flexion (14,15). It has been observed in people performing repetitive motion requiring tasks, tennis players, discus throwers and also in violin players (7). In a few cases paralysis has been observed following application of a compressive bandage or deep local massage of the epicondylitis. 3 of our patients (occupation mechanic and electrician) were performing repetitive motion tasks with their dominant arm. One of our patients was an electrician [case 8] who developed clinical complaints in his left hand wrist since he was left-handed. Besides, during surgical exploration the incised supinator muscle was observed to be too hypertrophic. If there is no dynamic compression, authors have reported that they obtained good results in combination with systemic and local anti-inflammatory medical treatment and physical therapy (19).

In general, RTS is a mainly dynamic nerve compression syndrome. The complaints of the patient were reported to finish when the patient stopped working and started resting. Therefore, the edema of the neural tissue and its environment should be expected (figure 2a). Recovery in the clinical progress is also expected with the disappearance of the edema at this site at the end of a period of 2-3 weeks. Radial nerve deep branch innervates numerous extensor muscles of the wrist and the hand after its passage through the tunnel. Pure motor paralysis is diagnosed owing to this characteristic of the nerve. Extensors of the hand remain healthy. Extensor carpi ulnaris and similarly, the extensors of the long-finger and the thumb are involved. Sometimes localized dorsal forearm pain near the elbow also accompanies the manifestation of pain.

RTS has been usually reported in 4 – 5. decades in clinical study of the literature (13,20). The average age of our study was younger (28 years). When looking at the gender distribution in our study, it was seen in young male. This situation, it was compatible with the common peroneal nerve entrapment why seen more common in young men (18). Few studies have compared the outcome of our surgical treatment. Jebson at al. performed radial tunnel surgical decompression with anterior approach to 31 patients and 33 extremities (19). The clinical states of 23 subjects and 24 extremities were controlled 8 years after the surgical decompression. Excellent results were obtained from 15 patients (67%). The states of 8 patients (33%) were described a little poor. 5 patients were reported to change job due to persistent job related impairment of comfort (19). Perez at al. operated for radial tunnel syndrome using a postero-lateral approach on 42 patients (43 extremities). Their outcomes; 21 patients (%48.8) no complaint, 16 patients (%37.2) occasional symptoms and 6 patients (%13.95) symptoms present with repetitive activities. Elbow mobility is complete in all patients, one patient except, all patients recovered wrist force. There are similarities between our results of the literature (3). Also, it was noticeable that there is a long duration times at Perez's work. The duration time in our patients has affected the amelioration of our clinical results. Even so, Complete clinical improvement was observed in all, except for one (%90). At the end of one-year-period in case 8, he could not perform the dorsal flexion of the hand and wrist. The presence of the problem in the dominant hand may lead to important results for the future. Because of the profession, It was observed to be more neurological damage in individuals exposed to repetitive micro-trauma. And, it need absolute surgical treatment for these types of cases. Eighteen percent of all patients with surgical treatment had improved after 2 weeks, and there were no correlations between neural compression time and the beginning of clinical improvement. Certain limits of surgical exploration time were not defined in the literature. However, the recommended exploration time is should be decided according to the diffusion process of edema around the neural tissue between a period of 3 and 9 weeks (21). Consequently, we wait for a period of time for a suddenly developing wrist drop manifestation. Besides, it is required to wait for peripheral nerve traumas to determine the degree of neurophysical impairments. EMG should be performed at least after 3 weeks to understand the presence of Wallerian degeneration. In the presence of an

actual pathological injury in the form of axonotmesis, findings of EMG referring to entrapment of the radial nerve are also detected. In the light of all positive findings, we made our decision on early surgical decompression.

Limitation of this study

The present study has some limitations. First, it is a retrospective study with a limited number of patients. Second, it focuses on the experience of a single center at a single city. Socio-economic and cultural status of the patients included into the study are similar. Depending on these, a universal generalization of the results can not be made for the evaluation of patients with hemiparesis. Different centers may have different experiences. And There is a few studies to compared the outcome of surgical treatment in literature

In conclusion

Following results can be drawn from this study; If motor conduction velocity (MCV) to less than 45 m/sec for radial nerve, It should be performed decompressive surgery. Improvement in patients undergoing conservative treatment may take 8 weeks. Final outcome of the patients undergoing surgery was found to be improved quickly and efficiently. Surgical decompression of the radial nerve appears to be beneficial in patients unresponsive to conservative treatment. Wrist drop is a clinical pathology more rarely seen than foot drop, which is one of the most important emergencies encountered in neurosurgical practice. However, if we detect this state, the necessity for an approach with the same sensitivity due to possible permanent sequelae should not be forgotten. Or results should be kept in mind.

Acknowledgement: We would like to thank Tuna Ferit HİDAYETOĞLU, a member of the academic staff of Erciyes University Faculty of Fine Arts, for his contribution to the manuscript with his detailed illustrations.

References

- [1] N. H. Naam and S. Nemani, "Radial Tunnel Syndrome," *Orthop. Clin. North Am.*, 2012; vol. 43, no. 4, pp. 529–536.
- [2] T. D. Tennent and A. Woodgate, "Posterior interosseous nerve dysfunction in the radial tunnel," *Curr. Orthop.* 2008; vol. 22, no. 3, pp. 226–232.
- [3] C. Simon Perez, B. García Medrano, J. I. Rodriguez Mateos, B. Coco Martin, O. Faour Martin, and M. A. Martin Ferrero, "Radial tunnel syndrome: results of surgical decompression by a postero-lateral approach.," *Int. Orthop.* 2014; vol. 38, no. 10, pp. 2129–2135,
- [4] R. Latinovic, M. C. Gulliford, and R. A. C. Hughes, "Incidence of common compressive neuropathies in primary care.," *J. Neurol. Neurosurg. Psychiatry*, Feb. 2006; vol. 77, no. 2, pp. 263–265.
- [5] J.-T. Lee, K. Azari, and N. F. Jones, "Long term results of radial tunnel release--the effect of co-existing tennis elbow, multiple compression syndromes and workers' compensation.," *J. Plast. Reconstr. Aesthet. Surg.* 2008; vol. 61, no. 9, pp. 1095–1099.
- [6] M. Ozkan, A. K. Bacakoglu, O. Gul, A. Ekin, and O. Magden, "Anatomic study of posterior interosseous nerve in the arcade of Frohse.," *J. shoulder Elb. Surg. / Am. Shoulder Elb. Surg. ... [et al.]*, 1999; vol. 8, no. 6, pp. 617–620.
- [7] N. Of, R. Nerve, and M. D. Guidelines, "Neuropathy of Radial Nerve (Entrapment)," 2015; pp. 1–7.
- [8] K. I. M. van den Ende and S. P. Steinmann, "Radial tunnel syndrome.," *J. Hand Surg. Am.*, Jun. 2010; vol. 35, no. 6, pp. 1004–1006.
- [9] A. C. Dang and C. M. Rodner, "Unusual compression neuropathies of the forearm, part I: radial nerve.," *J. Hand Surg. Am.*, Dec. 2009; vol. 34, no. 10, pp. 1906–1914.
- [10] C. C. Review, "Radial Tunnel Syndrome, Diagnostic and Treatment Dilemma," 2015; vol. 156, no. 3, pp. 156–162.
- [11] G. D. Ritts, M. B. Wood, and R. L. Linscheid, "Radial tunnel syndrome. A ten-year surgical experience.," *Clin. Orthop. Relat. Res.*, Jun. 1987; no. 219, pp. 201–205.
- [12] T. Prasaritha, P. Liupolvanish, and A. Rojanakit, "A study of the posterior interosseous nerve (PIN) and the radial tunnel in 30 Thai cadavers.," *J. Hand Surg. Am.*, Jan. 1993; vol. 18, no. 1, pp. 107–112.

- [13] B. R. Han, Y. J. Cho, J. S. Yang, S. H. Kang, and H. J. Choi, "Clinical features of wrist drop caused by compressive radial neuropathy and its anatomical considerations.," *J. Korean Neurosurg. Soc.* 2014; vol. 55, no. 3, pp. 148–151.
- [14] E. Fernandez, R. Pallini, and G. Talamonti, "Sleep palsy (Saturday-night palsy) of the deep radial nerve. Case report.," *J. Neurosurg.*, Mar. 1987; vol. 66, no. 3, pp. 460–461.
- [15] K. Kalb, P. Gruber, and B. Landsleitner, "[Compression syndrome of the radial nerve in the area of the supinator groove. Experiences with 110 patients].," *Handchirurgie, Mikrochirurgie, Plast. Chir. Organ der Deutschsprachigen Arbeitsgemeinschaft für Handchirurgie Organ der Deutschsprachigen Arbeitsgemeinschaft für Mikrochirurgie der Peripher. Nerven und Gefässe Organ der Vereinigung der Deut.*, Sep. 1999; vol. 31, no. 5, pp. 303–310.
- [16] M. Konjengbam and J. Elangbam, "Radial nerve in the radial tunnel: anatomic sites of entrapment neuropathy.," *Clin. Anat.*, Jan. 2004; vol. 17, no. 1, pp. 21–25.
- [17] A. Kanat, M. S. Balik, S. Kirbas, B. Ozdemir, V. Koksall, U. Yazar, H. Kazdal, and A. Kalaycioglu, "Paradox in the cubital tunnel syndrome—frequent involvement of left elbow: first report," *Acta Neurochir. (Wien)*, 2014; vol. 156, no. 1, pp. 165–168.
- [18] S. Kayacı, V. Köksal, and S. Kirbaş, "Peroneal Sinir Felci: Ameliyat Edilen Sekiz Olgunun Özellikleri ve Tedavi Sonuçları," *SiSli Etfal Hastan. Tip Bul. / Med. Bull. Sisli Hosp.*, 2014; no. 2, pp. 141–145.
- [19] P. J. Jebson and W. D. Engber, "Radial tunnel syndrome: long-term results of surgical decompression.," *J. Hand Surg. Am.*, Sep. 1997; vol. 22, no. 5, pp. 889–896.
- [20] M. a J. Bolster and X. R. Bakker, "Radial tunnel syndrome: emphasis on the superficial branch of the radial nerve.," *J Hand Surg Br*, 2009; vol. 34, no. 3, pp. 343–347.
- [21] D. G. Sotereanos, S. E. Varitimidis, P. N. Giannakopoulos, and J. G. Westkaemper, "Results of surgical treatment for radial tunnel syndrome.," *J. Hand Surg. Am.*, May. 1999; vol. 24, no. 3, pp. 566–570.